

Evolution[®] Biliary in Relief of Malignant Obstruction



*Mankanwal Singh Sachdev, MD
Director, Arizona Center for
Digestive Health
Director of Endoscopic Ultrasound
Banner Good Samaritan Hospital
Phoenix, AZ*

Indication and Devices

Once a malignant and nonresectable biliary obstruction is discovered, a metal stent is typically used to resolve the issue. In addition, an 8.5 mm (injection above) Cook Fusion Quattro Extraction Balloon, an Acrobat Calibrated Tip Wire Guide and a Fusion OMNI-Tome were used.

Presentation, Diagnosis and Outcome

A 70-year-old patient presented as an outpatient for symptomatic cholelithiasis and a laproscopic cholecystectomy was ordered and then performed. Prior to this, a CT was done, which revealed a lesion in the liver and a dilated bile duct. During surgery, the intraoperative cholangiogram was suggestive for a stricture in the bile duct, and liver biopsy was performed.

After this, a MRCP was ordered, which confirmed the presence of a stricture. ERCP was done next and the stricture was biopsied with standard biopsy forceps, brushed and then stented with a 10 Fr by 12 cm stent. (Figures 1-3) The patient did well initially, and liver enzymes came down. The patient's jaundice improved and in the subsequent days both the liver biopsy and bile duct biopsy came back positive for adenocarcinoma.

Approximately 2 weeks after stent placement, the patient presented with signs and symptoms of biliary obstruction. A second ERCP was performed, which revealed that the stent had become occluded with blood. At this point the stent was removed, the duct was cleaned using a balloon and a new stent was placed. A metal stent was not entertained at this point, because one was not available.

The patient was discharged and did well for another two weeks but then once again presented with obstruction and then cholangitis. The second stent was removed during ERCP and a 10 mm by 10 cm uncovered Evolution Controlled-Release metal stent was placed. Complete drainage of bile was achieved. (Figures 4-6) ■

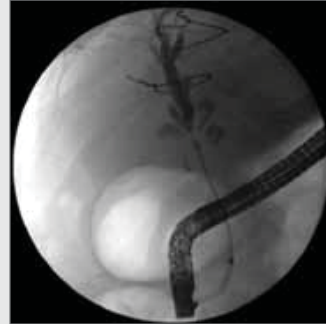


Figure 1

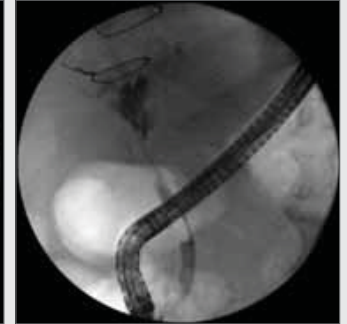

Figure 2

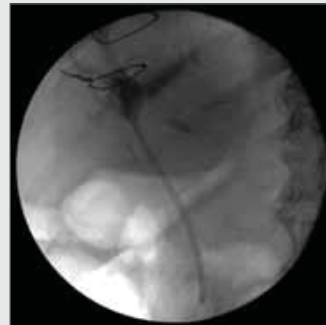

Figure 3

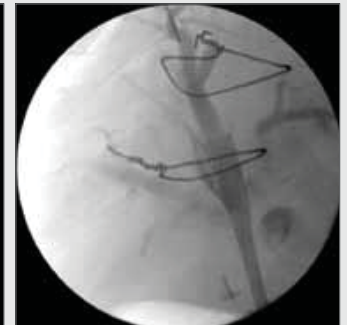

Figure 4

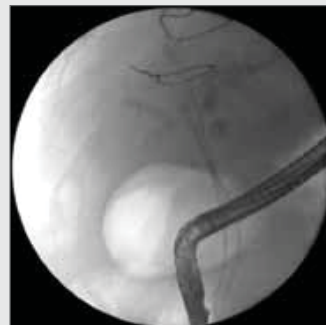

Figure 5

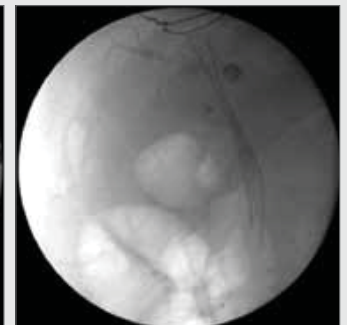


Figure 6