

Providing a Definitive Diagnosis of Cholangiocarcinoma for a Patient who Underwent 4 Failed Diagnostic Tests



Farhoud Khosravi, D.O.

Advanced Endoscopy Fellow,
Arizona Center for
Digestive Health
Gilbert, AZ



Mankanwal Singh Sachdev, M.D.

Director of Endoscopy
St. Joseph's Hospital and
Medical Center
Assistant Professor of Medicine
Creighton University School of
Medicine
University of Arizona -Phoenix
Co-Program Director Advanced
Therapeutic Endoscopy Fellowship
Gilbert, AZ



**Ananya Das,
M.D., FACP,
FASGE**

Chair of Gastroenterology
St. Joseph's Hospital and
Medical Center
Professor of Medicine
Creighton University
Director Arizona Center for
Digestive Health
Gilbert, AZ

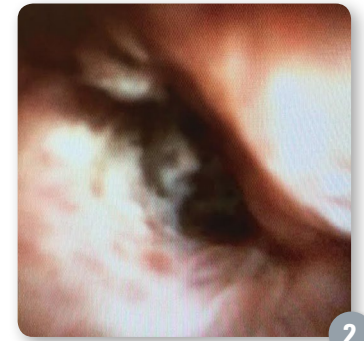
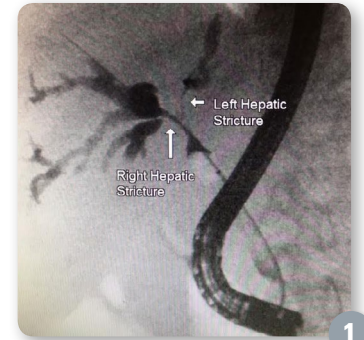
technique spotlight

Patient History

A 64-year-old female presented with jaundice, chills, and progressive fatigue. The patient was well until 3 months earlier when she was diagnosed with a hilar mass, causing suspicion of cholangiocarcinoma. An ERCP at that time revealed right and left hepatic duct strictures (Figure 1). She was successfully decompressed with the placement of two plastic biliary stents into the left and right hepatic systems. She then underwent an extensive work-up including biliary brushings via ERCP, two EUS procedures with FNA, and an exploratory laparotomy with hepatic wedge resection of suspected metastatic disease. Unfortunately, pathology from the above examinations failed to yield a diagnosis. Given the suspicion for cholangitis, an ERCP was recommended for biliary decompression via stent removal. In addition, cholangioscopy with biopsy using the SpyGlass™ DS System and SpyBite™ Biopsy Forceps was recommended to aid in establishing a diagnosis.

Procedure

An ERCP was performed and two occluded biliary plastic stents were noted with no bile flow into the duodenum. The stents were removed and deep cannulation of the CBD into the right hepatic duct was achieved over a 0.035" guidewire using a sphincterotome. Once the wire was in place, a retrieval balloon was used and copious purulent fluid was drained from the bile duct. Next, a cholangiogram was performed (Figure 1), which revealed a 15 mm stricture of the right hepatic and a very tight ~15mm stricture of the left hepatic duct. At this point, the balloon was exchanged for the SpyGlass DS System's SpyScope™ DS Access and Delivery Catheter, which was used to directly examine the right and left hepatic



Providing a Definitive Diagnosis of Cholangiocarcinoma for a Patient who Underwent 4 Failed Diagnostic Tests

technique spotlight

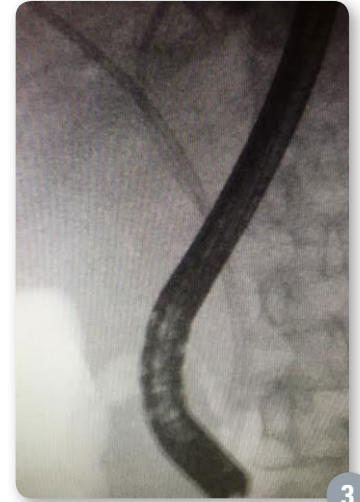stricture was easier to access and revealed significant narrowing, loss of vascular pattern with congested, erythematous and friable mucosa (Figure 2). Next, the SpyBite Biopsy Forceps were introduced and a direct biopsy of the right hepatic stricture was performed. The patient was then decompressed with successful placement of a 10Fr x 12cm Advanix™ Biliary Stent into the right hepatic duct and a 7Fr x 15cm Advanix Biliary Stent into the left hepatic duct (Figure 3).

Post-Procedure

The patient did very well and did not experience any complications. Her liver biochemistry completely normalized within 4 days, and her jaundice and fever were also resolved. Biopsies of the right hepatic duct stricture taken under direct visualization with SpyBite™ Biopsy Forceps confirmed adenocarcinoma, consistent with cholangiocarcinoma.

Discussion

This case demonstrates the utility of the SpyGlass™ DS System using SpyBite Biopsy Forceps in achieving tissue diagnosis in an otherwise elusive case. The patient underwent 4 modalities (biliary brushing, two EUS with FNA and exploratory laparotomy) for obtaining tissue from this hilar mass prior to our examination, all of which were non-diagnostic. Fortunately, the SpyGlass DS System with SpyBite Biopsy Forceps helped provide a definitive diagnosis and helped guide her oncologic management.



Providing a Definitive Diagnosis of Cholangiocarcinoma for a Patient who Underwent 4 Failed Diagnostic Tests

technique spotlight

Potential Economic Impact (US Only)

Earlier use of the SpyGlass DS System may have helped to avoid an exploratory laparotomy with hepatic wedge resection, potentially saving the hospital system \$20,111 in surgical costs.

ICD-9 Principal Procedure Code	Code Description	Costs, \$ (median)
50.22	Partial hepatectomy	\$20,111

Earlier use of the SpyGlass DS System may have helped to avoid several outpatient procedures costing between \$1,689 and \$2,187.*

CPT® Code	Code Description	2015 Medicare Geometric Mean Cost - Outpatient
43260	Endoscopic retrograde cholangiopancreatography (ERCP); diagnostic, including collection of specimen(s) by brushing or washing, when performed (separate procedure)	\$2,187
43242	Esophagogastroduodenoscopy, flexible, transoral; with transendoscopic ultrasound-guided intramural or transmural fine needle aspiration/biopsy(s) (includes endoscopic ultrasound examination of the esophagus, stomach, and either the duodenum or a surgically altered stomach where the jejunum is examined distal to the anastomosis)	\$1,689

*Source: Medicare's CY 2017 OPPS Cost Statistic File

The potential economic impact identified in this case only takes into account surgical and/or procedural costs avoided and does not take into account reimbursement. CPT copyright 2015 American Medical Association. All rights reserved. CPT is a registered trademark of the American Medical Association. Applicable FARS/DFARS Restrictions Apply to Government Use. Fee schedules, relative value units, conversion factors and/or related components are not assigned by the AMA, are not part of CPT, and the AMA is not recommending their use. The AMA does not directly or indirectly practice medicine or dispense medical services. The AMA assumes no liability for data contained or not contained herein.

Health economic and reimbursement information provided by Boston Scientific Corporation is gathered from third-party sources and is subject to change without notice as a result of complex and frequently changing laws, regulations, rules and policies. This information is presented for illustrative purposes only and does not constitute reimbursement or legal advice. Boston Scientific encourages providers to submit accurate and appropriate claims for services. It is always the provider's responsibility to determine medical necessity, the proper site for delivery of any services and to submit appropriate codes, charges, and modifiers for services that are rendered. Boston Scientific recommends that you consult with your payers, reimbursement specialists and/or legal counsel regarding coding, coverage and reimbursement matters. Boston Scientific does not promote the use of its products outside their FDA-approved label.

Results from case studies are not predictive of results in other cases. Results in other cases may vary. All trademarks are the property of their respective owners. Indications, Contraindications, Warnings and Instructions for Use can be found in the product labeling supplied with each device.

CAUTION: Federal (USA) law restricts this device to sale by or on the order of a physician

CAUTION: The law restricts these devices to sale by or on the order of a physician. Indications, contraindications, warnings and instructions for use can be found in the product labelling supplied with each device. Information for use only in countries with applicable health authority registrations. Material not intended for use in France.

Boston Scientific Corporation
300 Boston Scientific Way
Marlborough, MA 01752-1234
www.bostonscientific.com/gastro
www.EndoSuite.com

©2016 Boston Scientific Corporation or its affiliates. All rights reserved.

ENDO-415318-AA September 2016

